

# **Nonunion of femoral neck fracture**

**Babak Siavashi MD.**

**Tehran University of Medical Sciences, Sina Hospital**

# Aim

- **define nonunion of femoral neck fracture**
- **fixation failure**
- **can choose the best treatment for it**

# Definition

- **after 6 months**
- **fixation failure**
- **change the position of head**

# **work up**

- **infection R/O**
- **ESR/CRP**
- **MRI / MARS**

# Pay attention to:

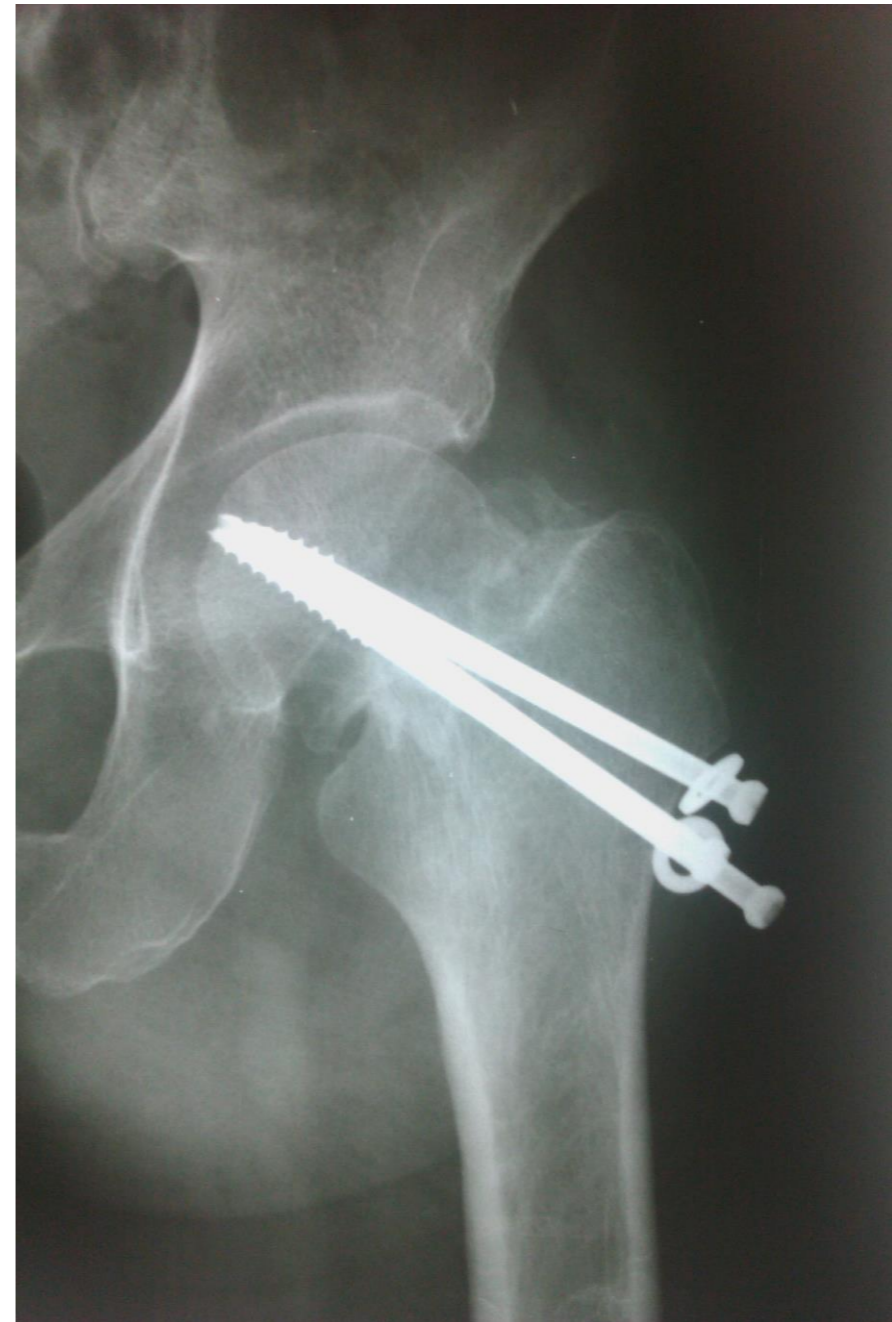- **age**
- **demand**
- **cartilage**
- **bone stock**
- **size of bone for fixation**
- **viability of head**
- **remaining neck portion**

# Options:

- **Hip Fusion (Arthrodesis)**
- **re osteosynthesis with or without graft**
- **Valgus osteotomy with or without graft**
- **total hip arthroplasty**

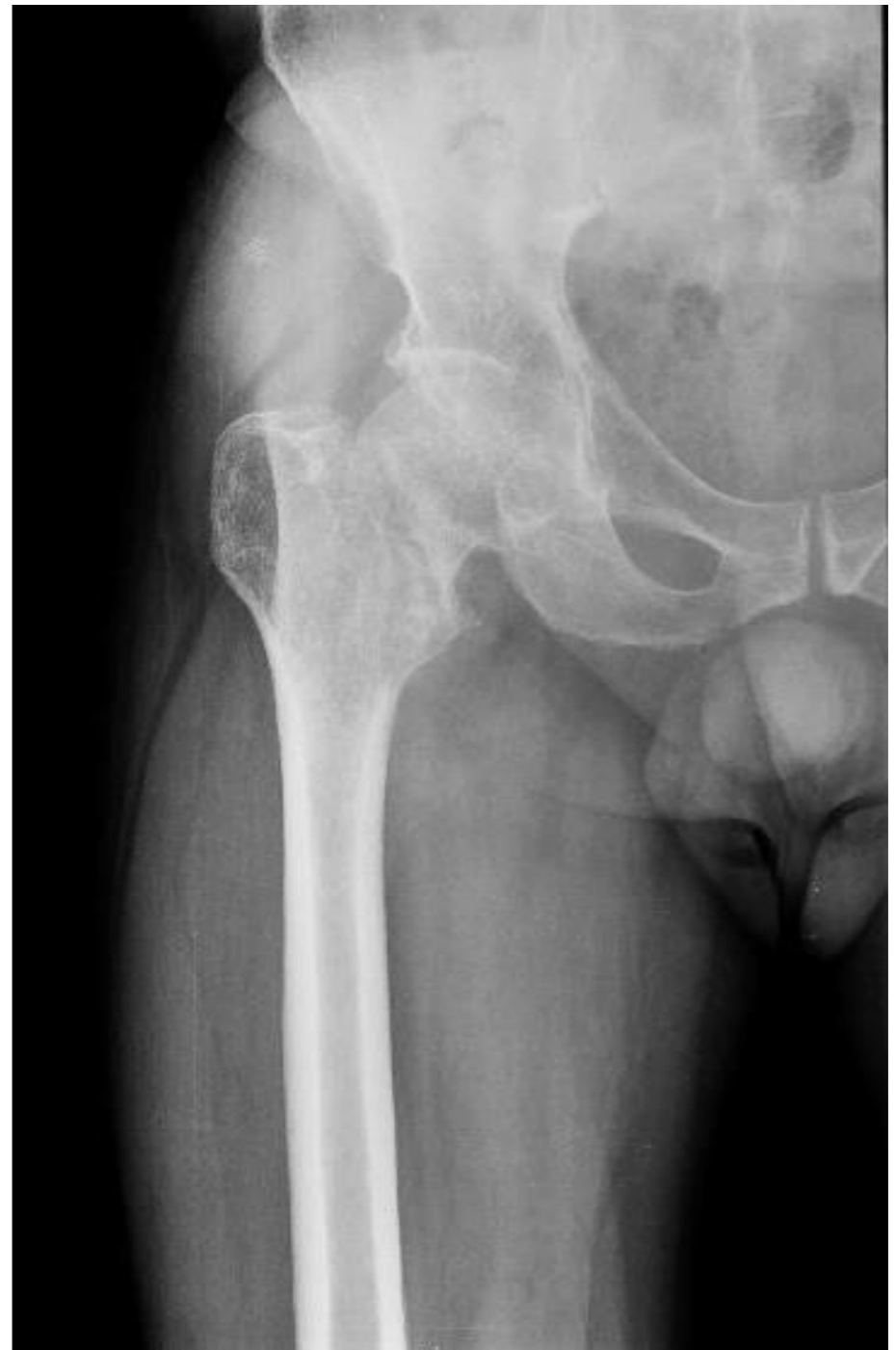# Reosteosynthesis +/- graft

- **early failure (less than 3 months)**
- **viable head**
- **good cartilage**
- **good bone stock**
- **sufficient size**
- **good neck**



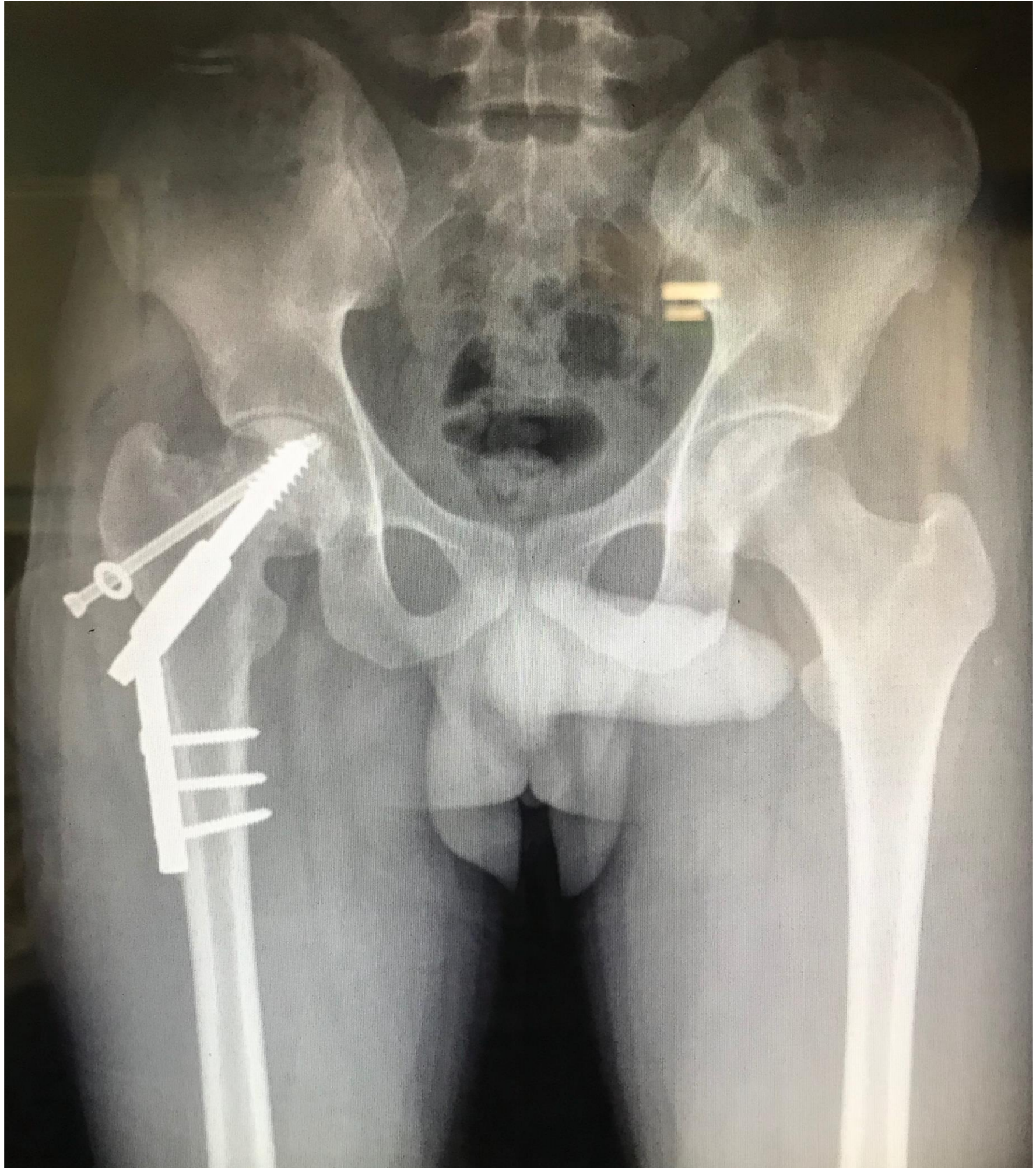
# Valgus osteotomy +/- graft

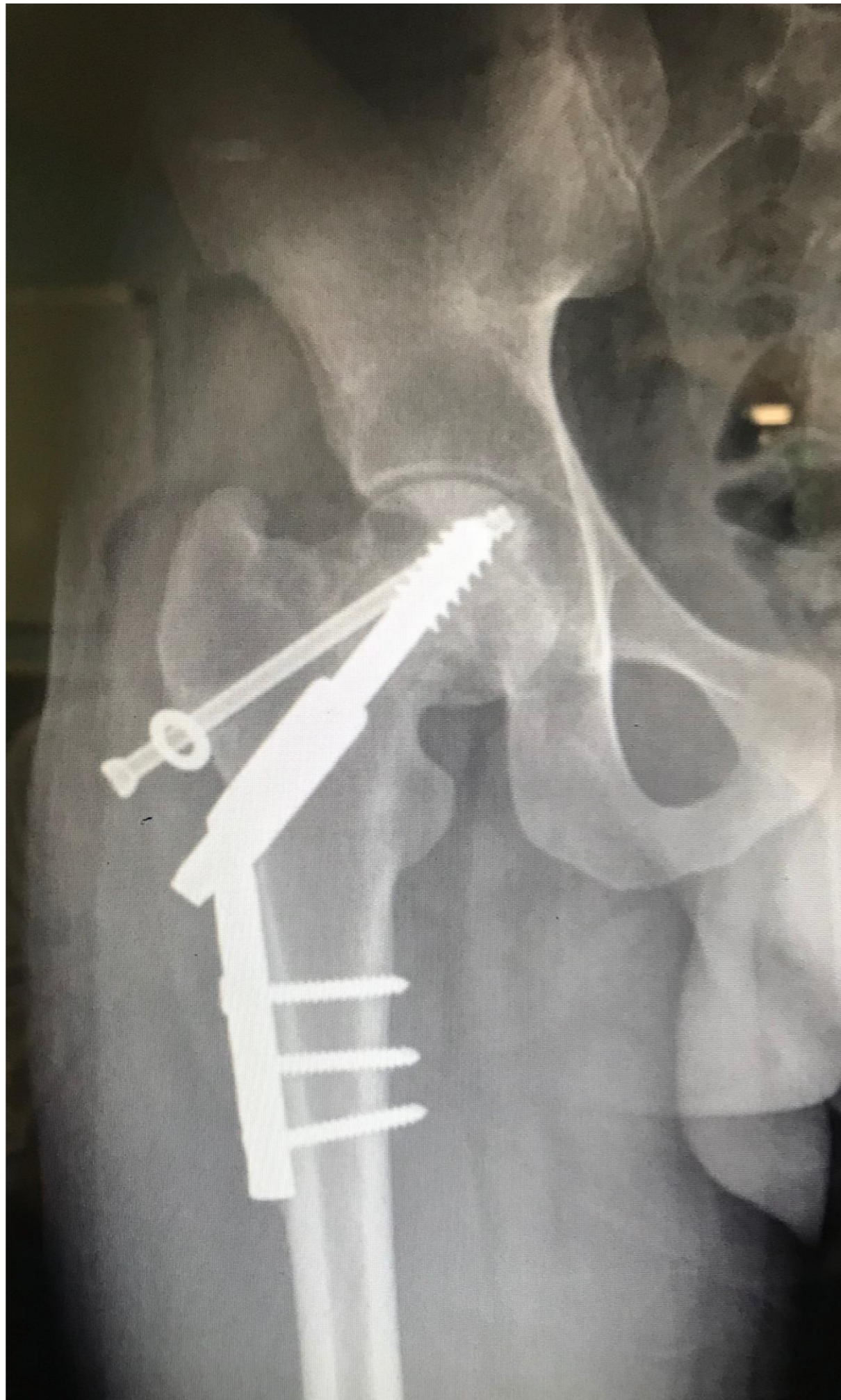- **More than 3 months from fracture**
- **viable head**
- **good cartilage**
- **good bone stock**
- **sufficient size**
- **good neck**

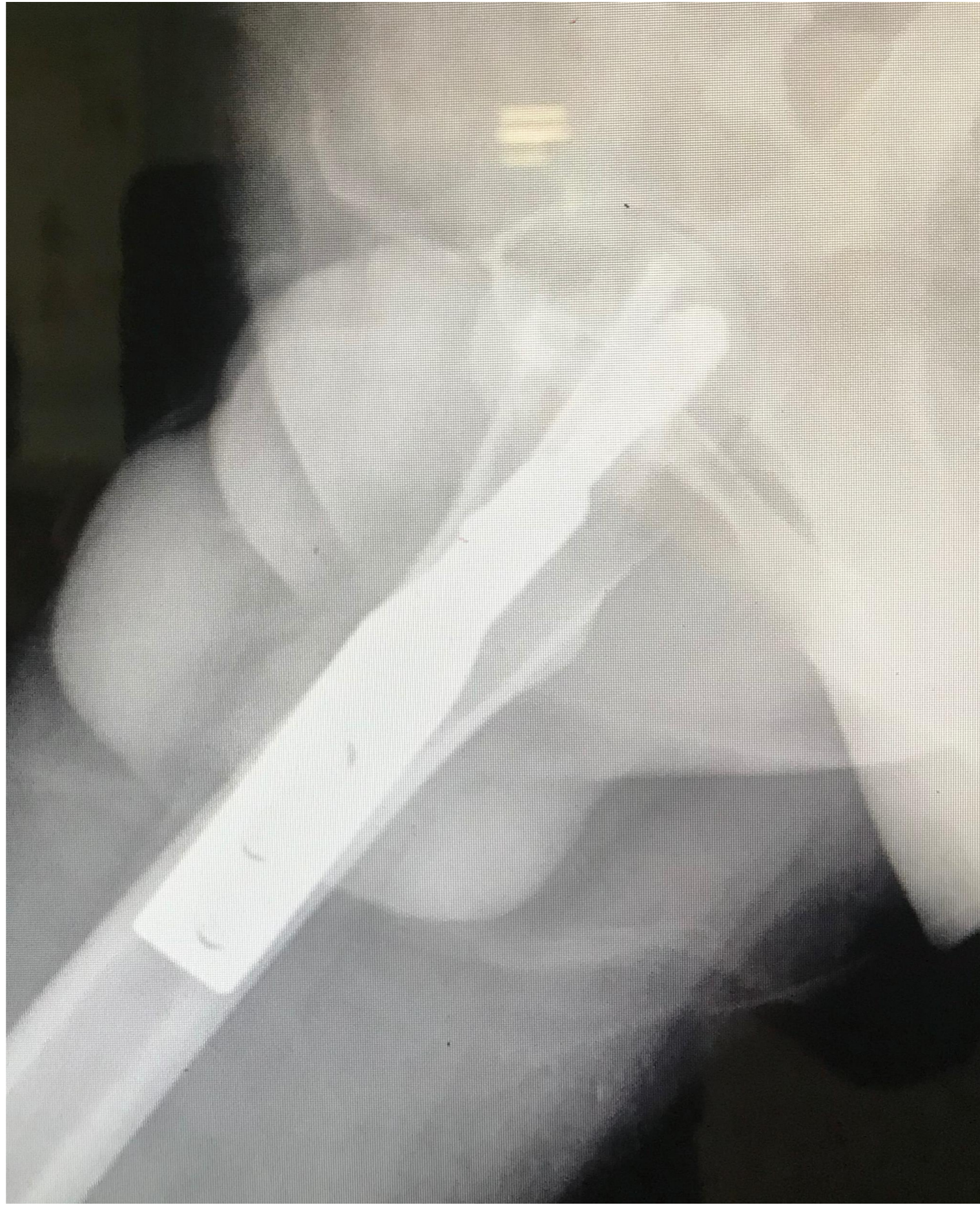

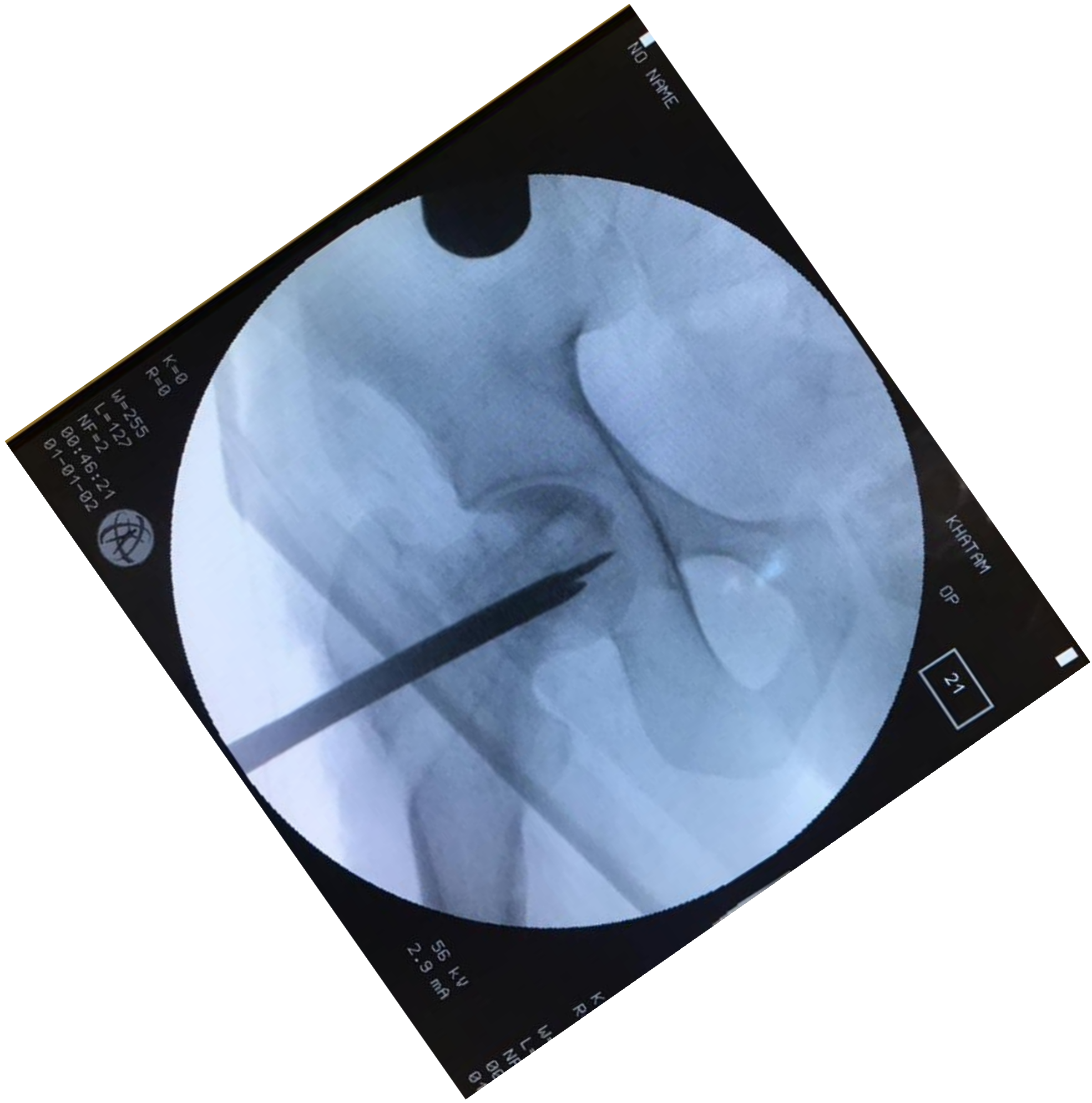


- **male**
- **24y**
- **6 months from index surgery**









NO NAME

K=0  
R=0  
W=255  
L=127  
NF=2  
00:46:21  
01-01-02



KHATAM

OP

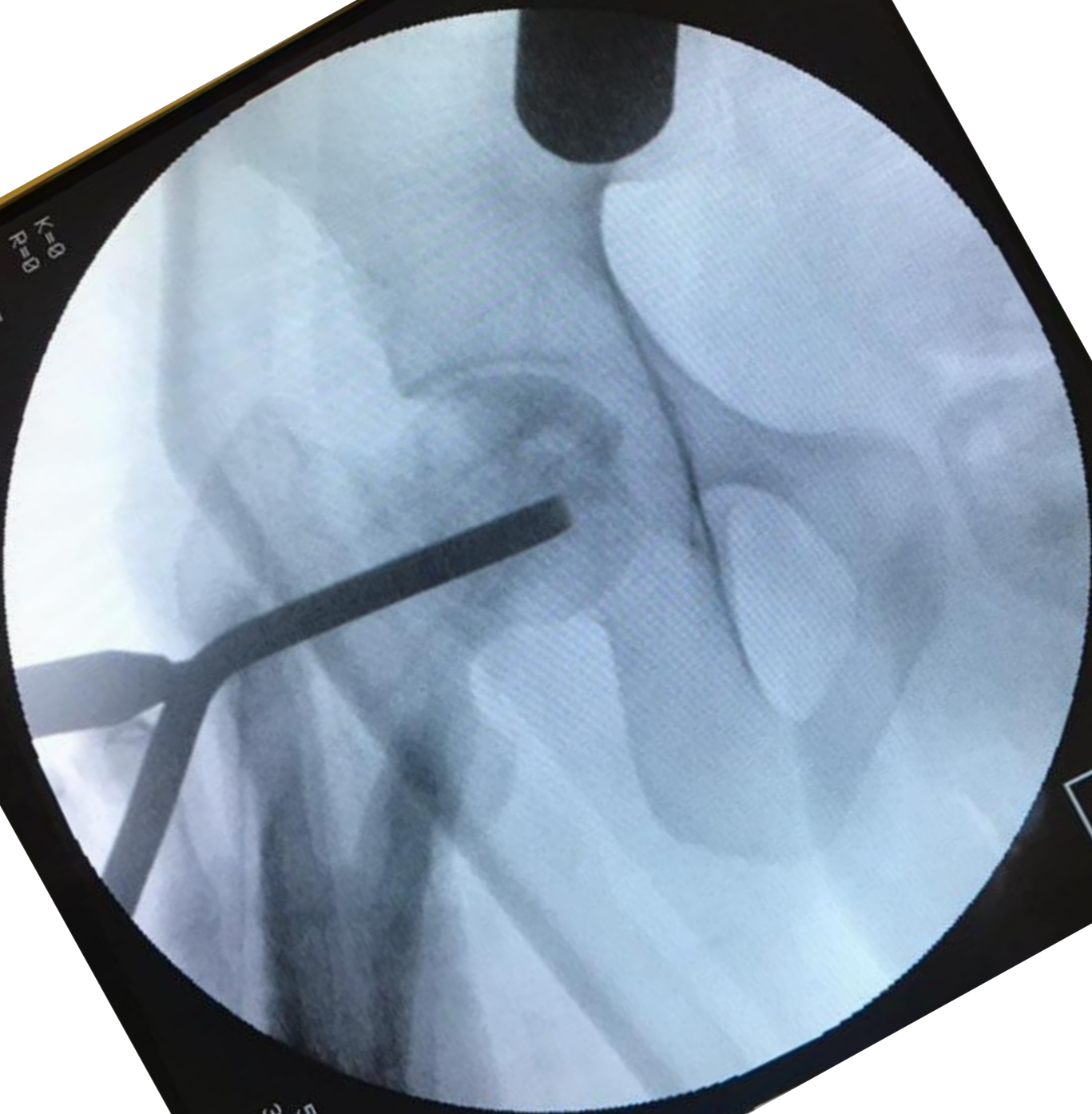

21

56 kV  
2.9 mA

00:46:21  
01-01-02  
L W  
R X

NO NAME

K=0  
R=0  
W=2555  
L=127  
NF=2  
00:58:00  
01-01-02



KHATAM  
OP

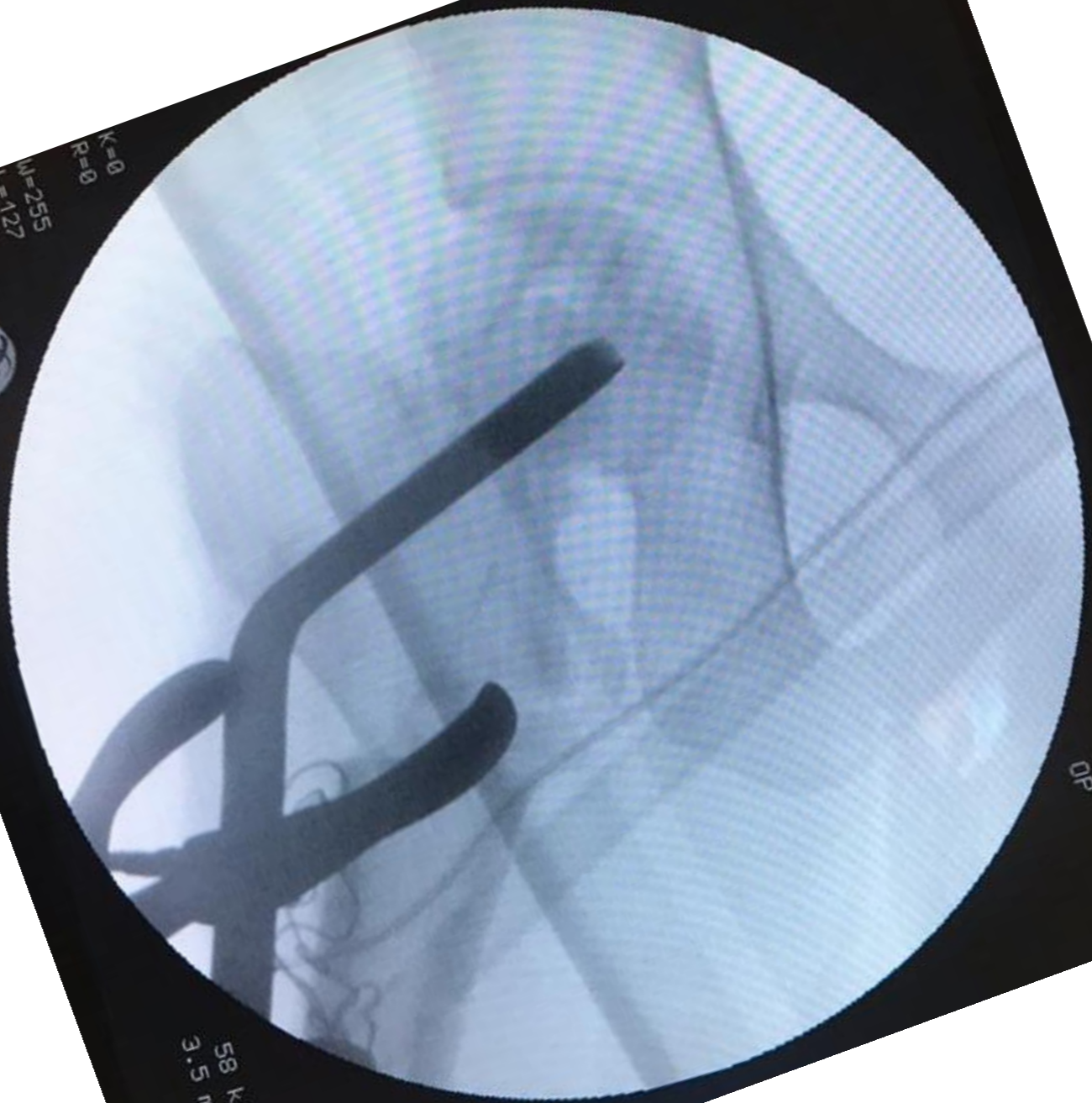
31

57 kV  
3.0 mA

000131  
000131

ID NAME

K=0  
R=0  
M=255  
L=127  
NF=2  
01:24:48  
91-01-02



KHATAM  
OP

58 kV  
3.5 mA

K R  
M=  
L=  
NF  
01  
01

NAME

5A  
5:55  
1-02

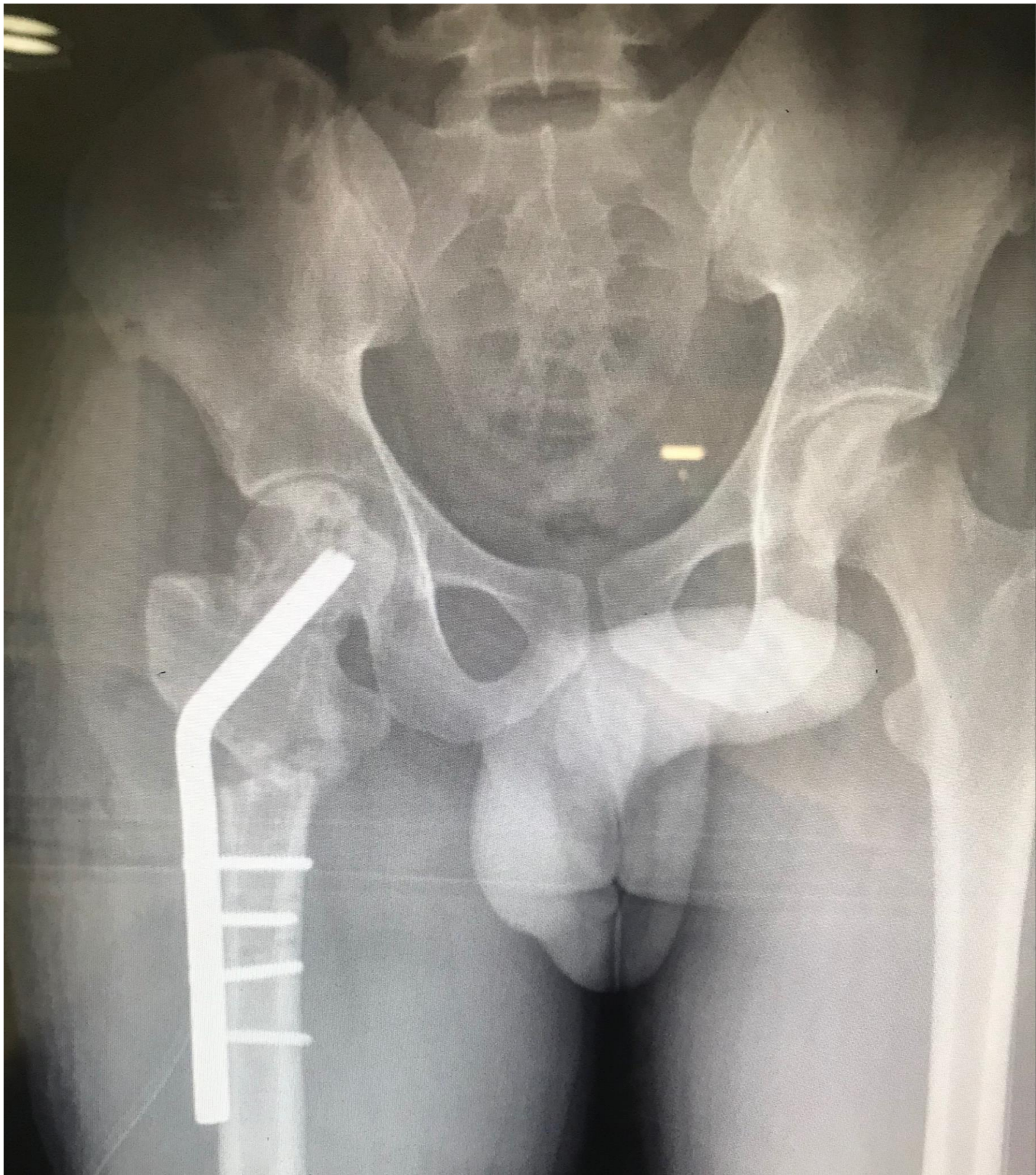

KHATAM  
OP

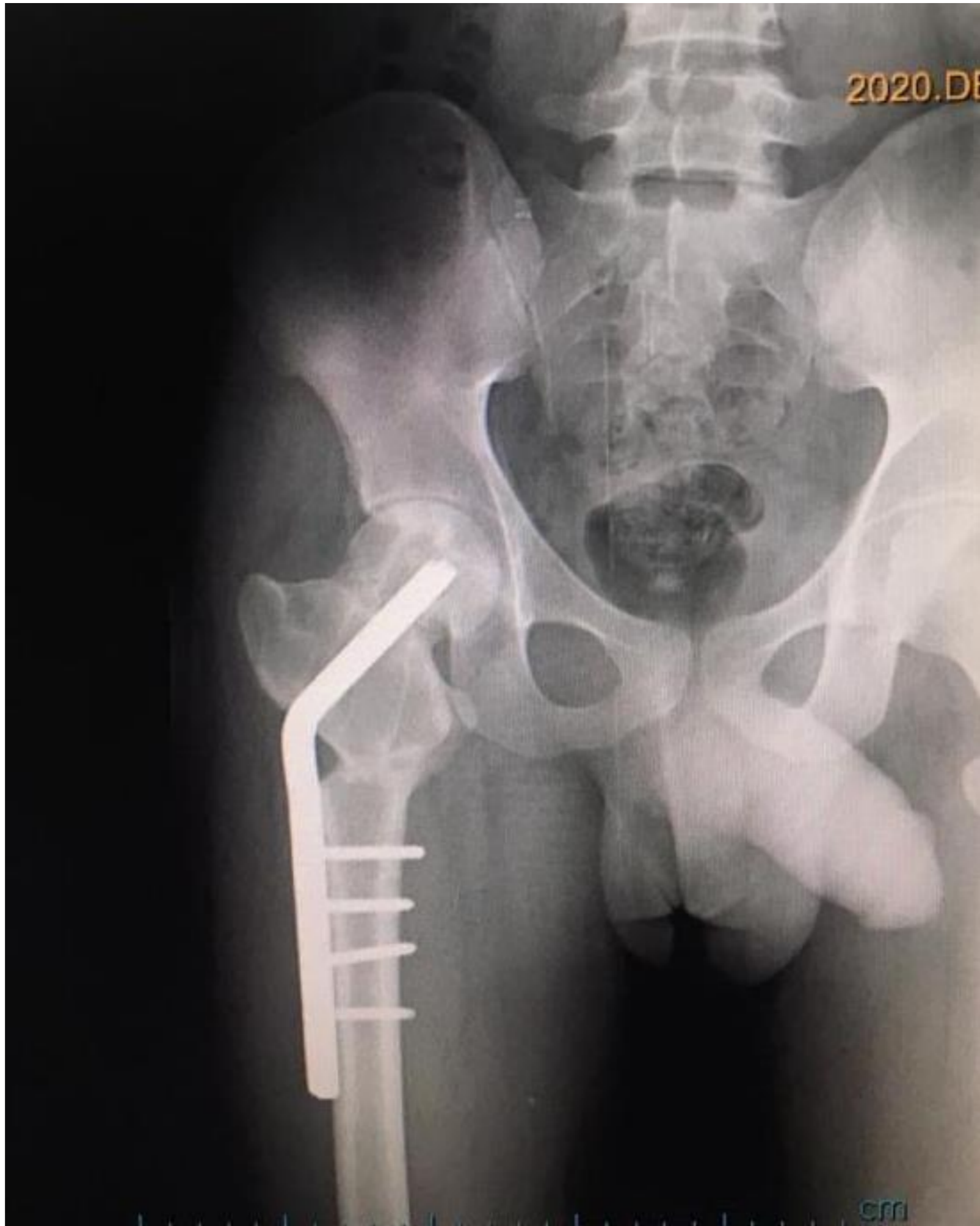56 kV  
2.9 mA

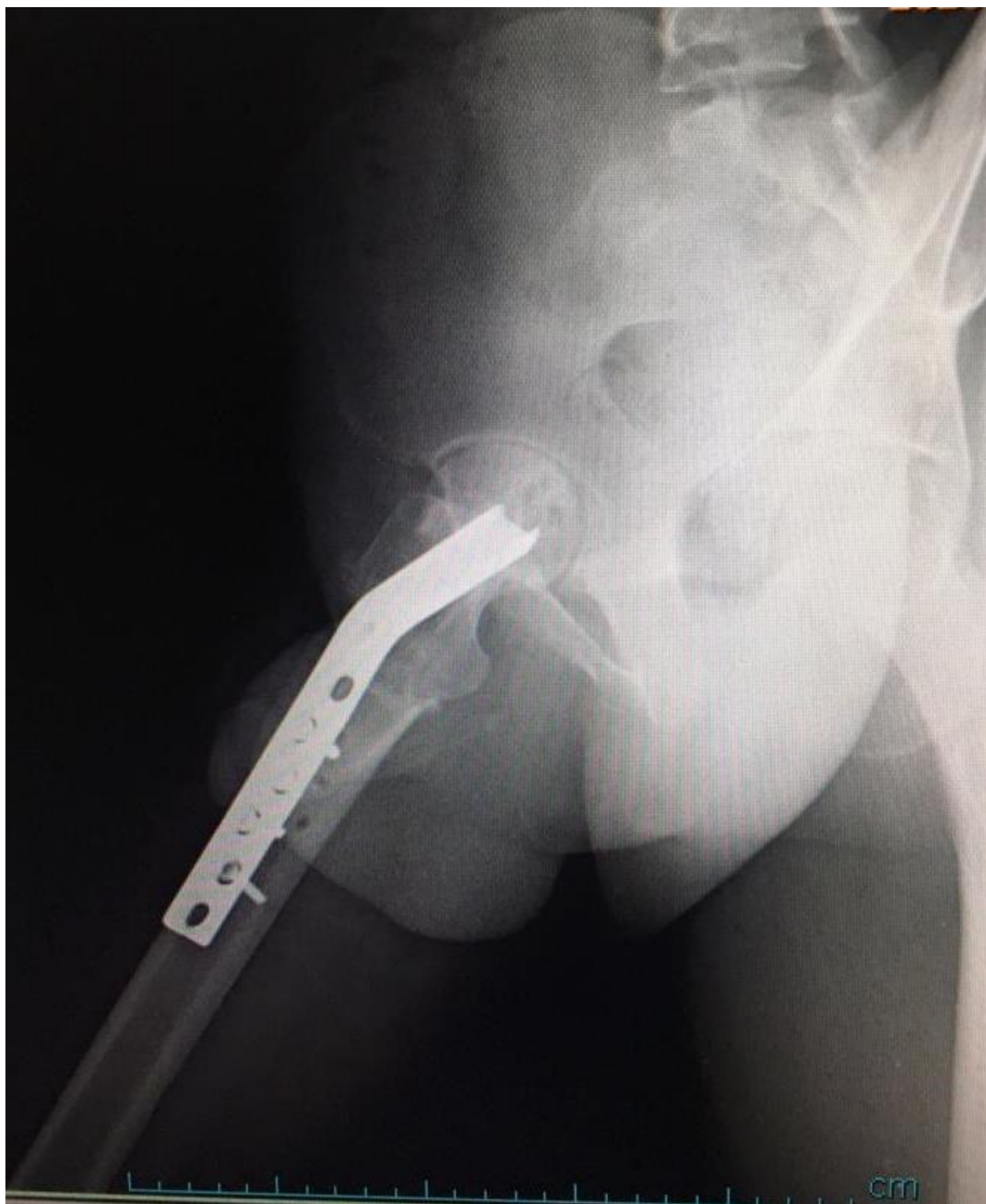NR  
L  
M  
R  
K



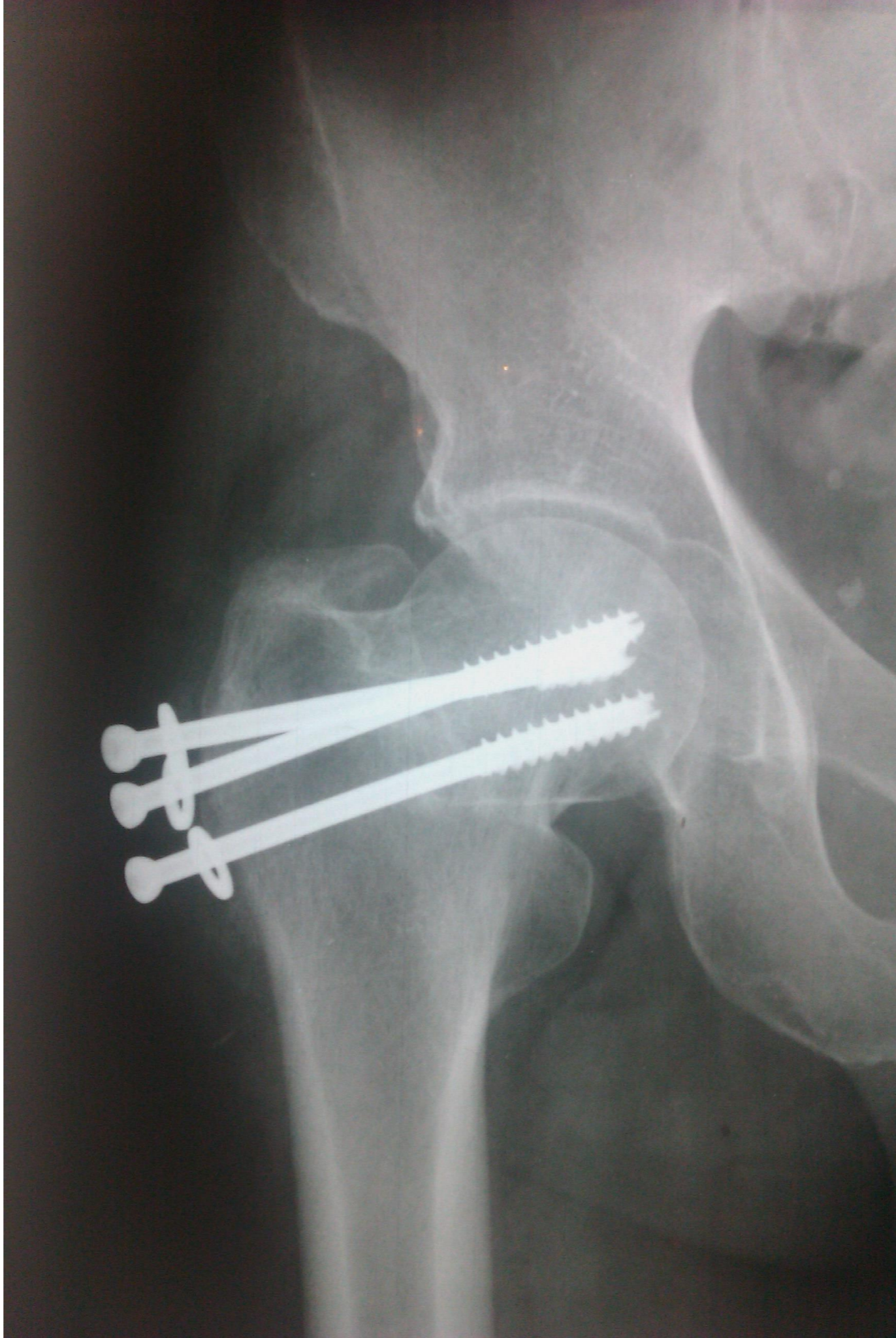


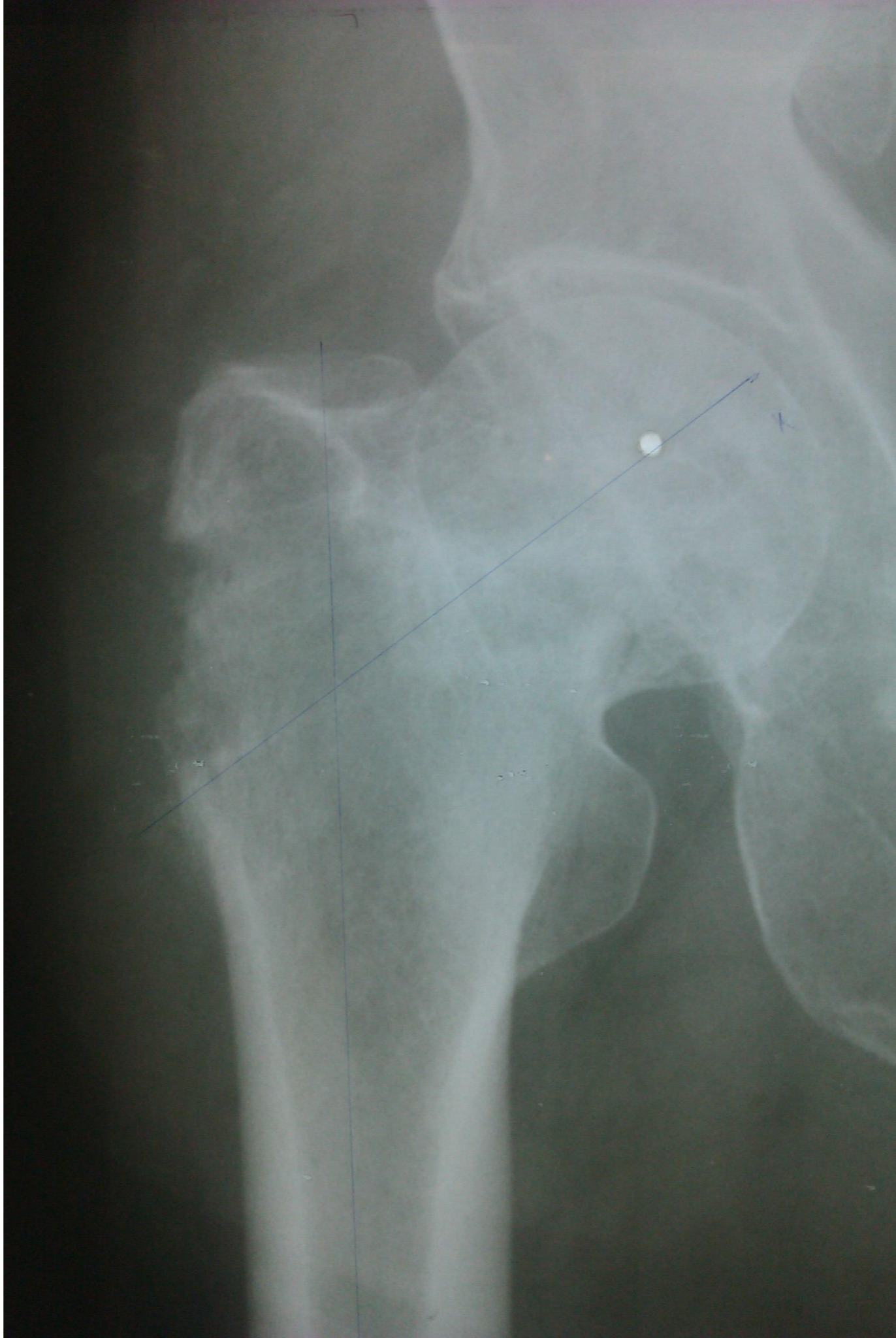**6 months later**





**other case**





**ic MRI**

MR scans with multiplanar images in different pulse sequences;

*Post operative changes in right hip and femoral neck are seen.*

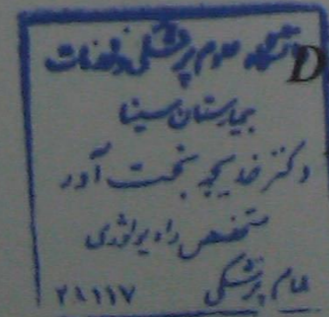
*Old non union fracture in the sub capital region of femoral neck seen with extension to the femoral head.*

*Joint effusion and marked soft tissue edema in surrounding periarticular tissue are seen which may be related to post operative changes.*

*There is no evidence of AVN in femoral head.*

*Abnormal signal in intrachontric region and femoral neck are noted.*

*The left hip appears normal. /61*



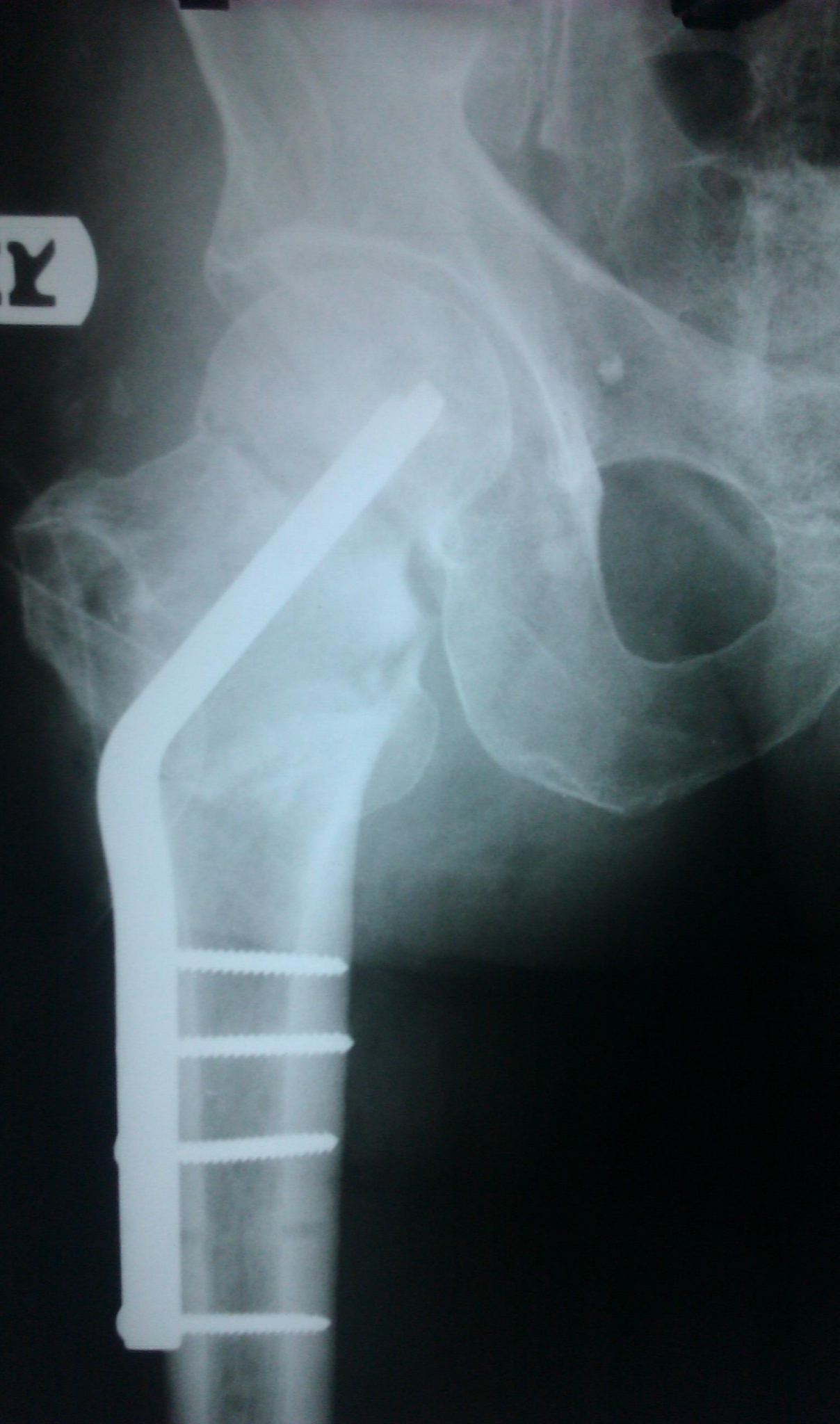
Dr. Bakhtavar

Radiologist

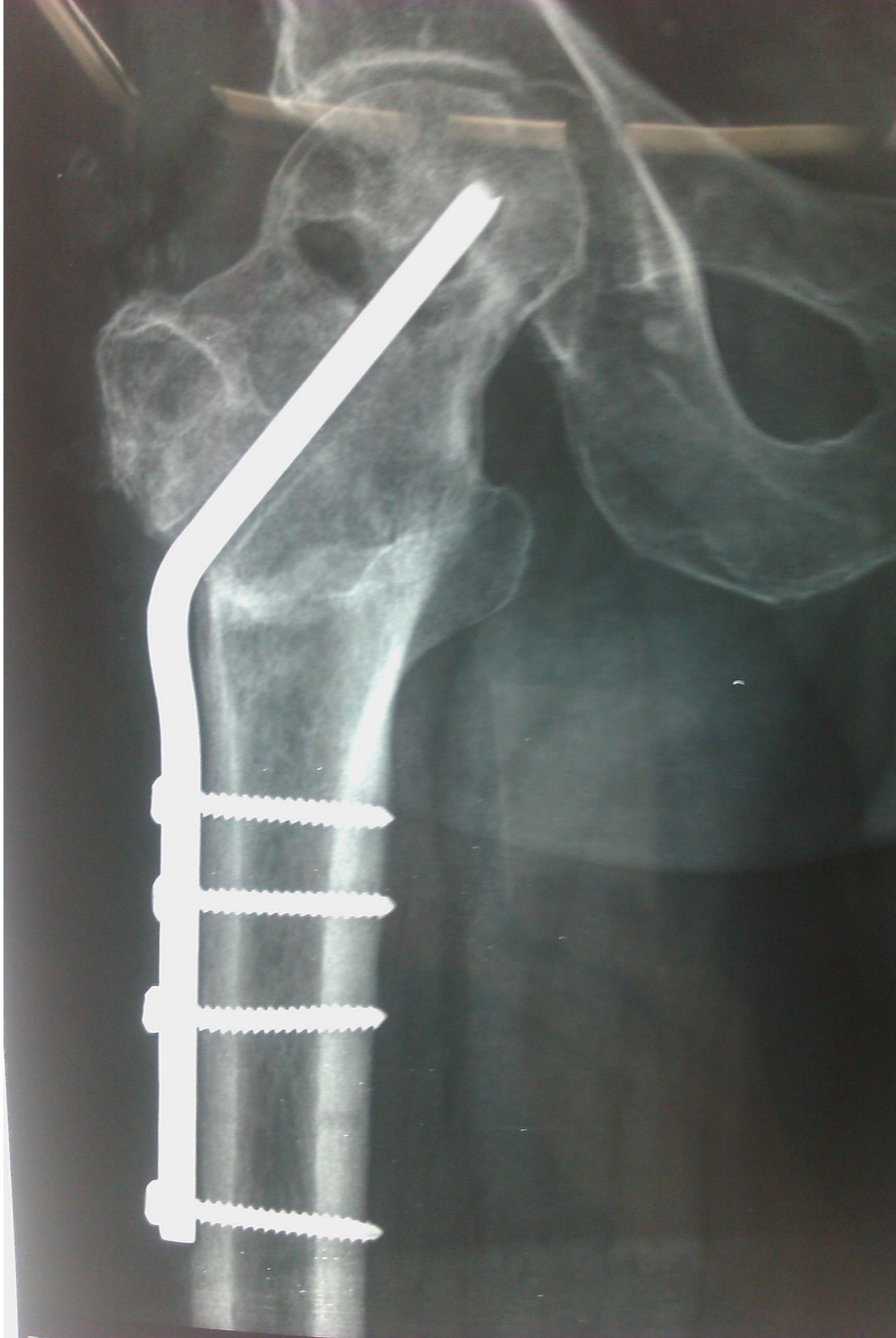90/11/15



29 IX

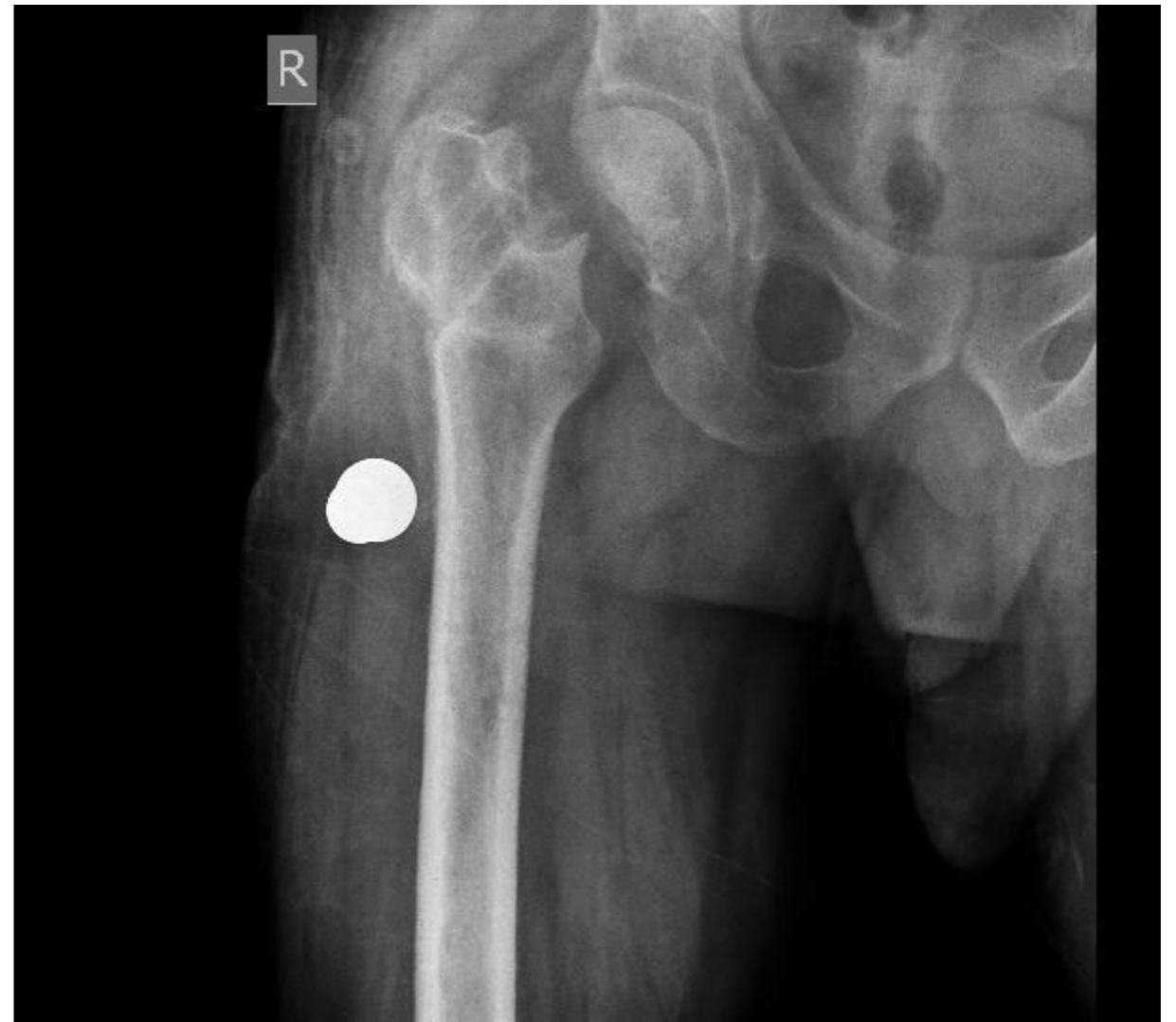

**6 months later**

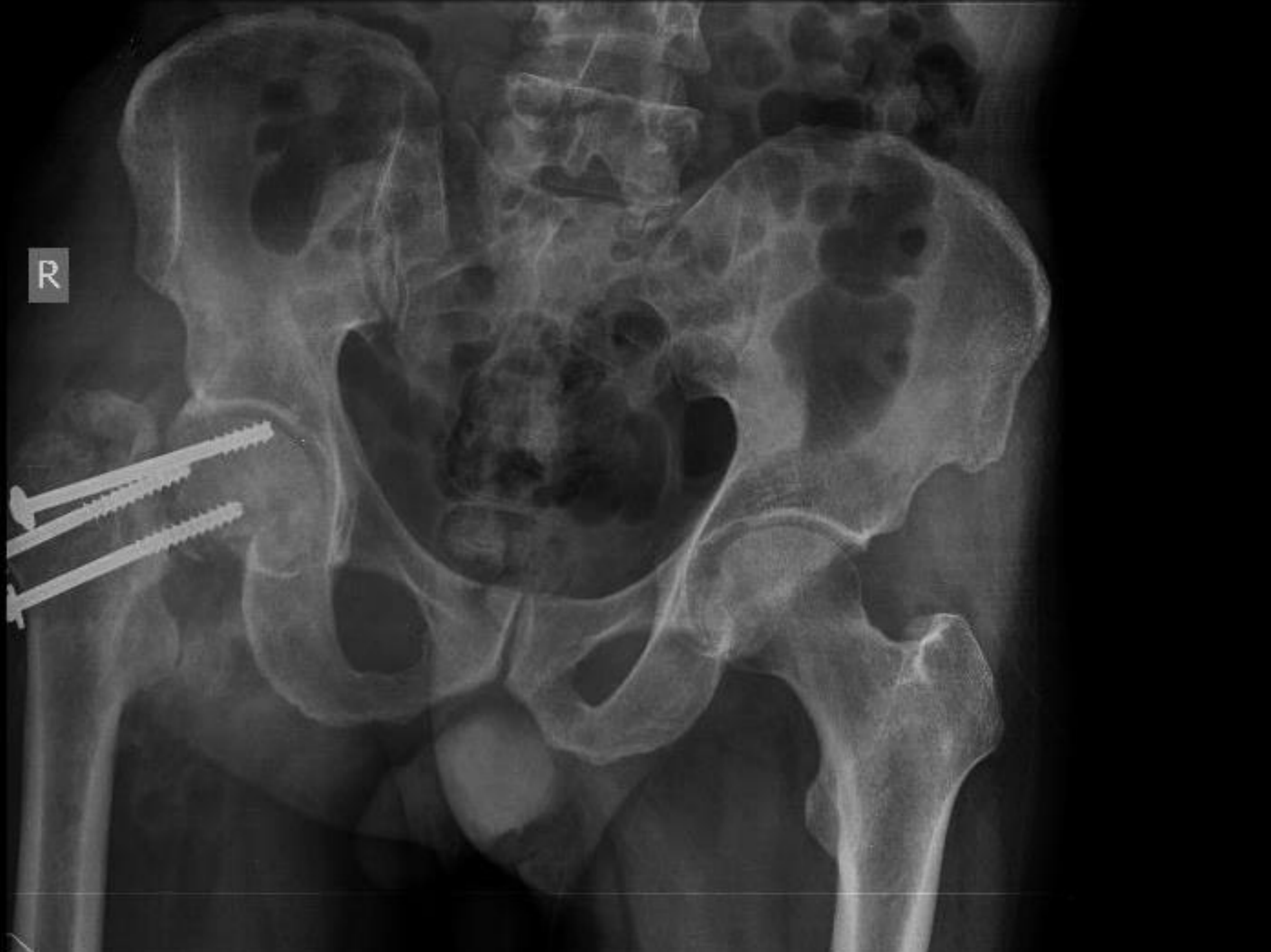

# Total hip arthroplasty

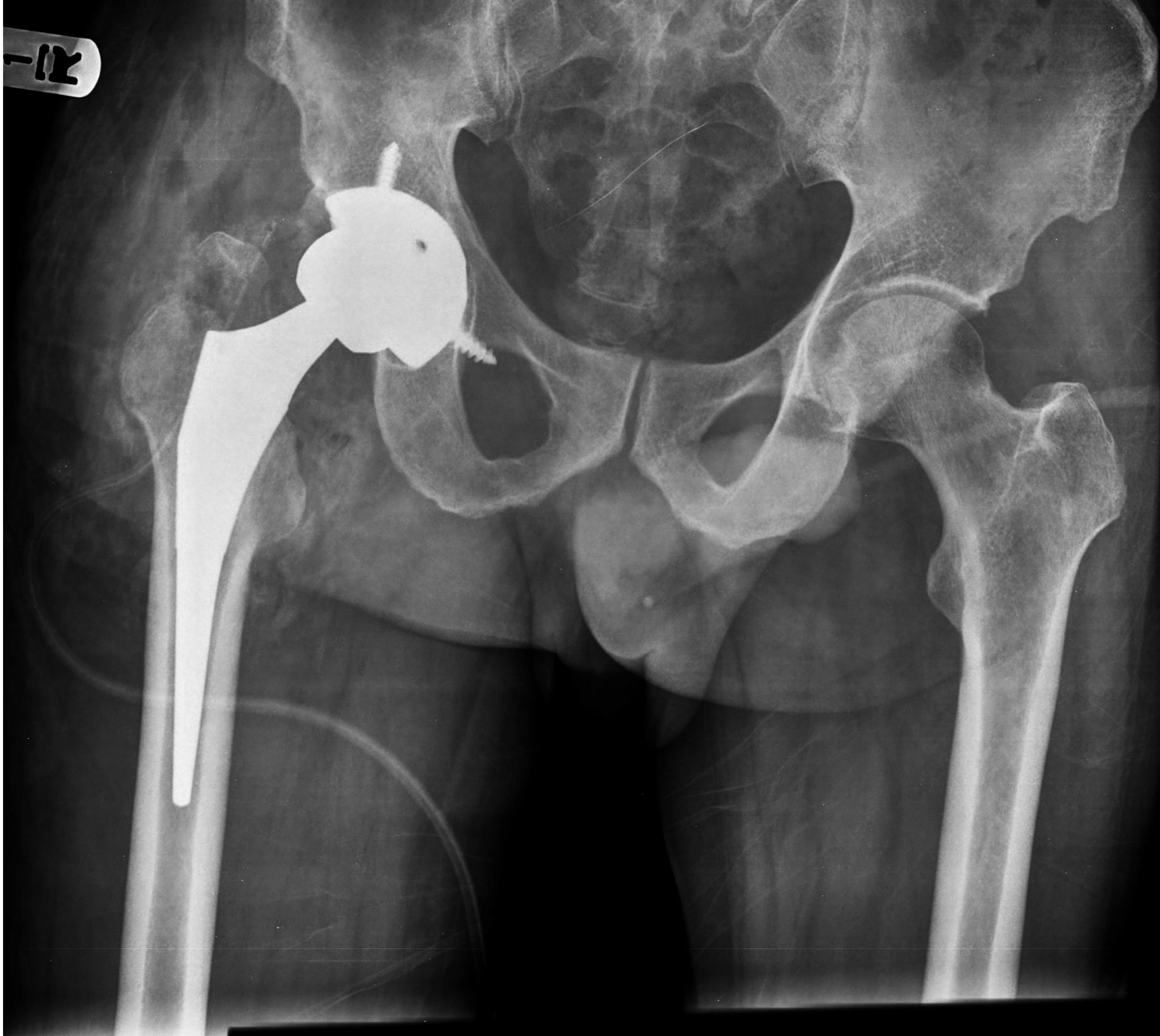- **no functional cartilage (decreased joint space)**
- **insufficient bone size**
- **insufficient bone stock (osteoporosis)**
- **insufficient neck**
- **active and functional**



R



12



# Summary

- **Look at cartilage, bone stock size, neck, viability**
- **if all of them are OK >>>>> valgus osteotomy**
- **if one of them is not present >>>>> THA**

**Thank you**